Robotic-Assisted Follicular Unit Extraction for Hair Restoration: Case Reports

James Harris, MD

Follicular unit extraction (FUE) is a graft harvest technique for hair restoration that offers the benefits of minimal postoperative pain and absence of linear scarring in the donor area. The demand for hair restoration procedures has rapidly increased, but the majority of physicians do not offer FUE as a treatment option for hair restoration because of the intensive training and experience required for proficiency. The ARTAS System (Restoration Robotics, Inc), a computer-assisted robotic technology used to perform FUE, received 510(k) clearance from the US Food and Drug Administration and enables more physicians to perform FUE by minimizing the traditional learning curve, which has slowed the adoption of this technique. This article presents 2 clinical cases of patients with androgenetic alopecia who were treated with FUE.

Cosmet Dermatol. 2012;25:284-287.

Hair restoration is a prevalent cosmetic procedure among men, and its popularity continues to grow.[1] The high demand for hair restoration procedures has created an impetus to offer better, less invasive treatments that are more widely available. This report of 2 cases of patients with hair loss demonstrates how new technology is impacting common hair restoration procedures.

HAIR RESTORATION SURGERY

The concept of extracting and grafting hair originated in Japan before World War II and has evolved from grafting relatively large segments of skin to implanting individual follicular units into small recipient sites. Based on Orentreich's[2] theory of donor dominance, hair restoration surgery is performed under the premise that hair growing in permanent regions, such as the sides and back of the head, is resistant to the hormonal causes of hair loss that are predominant in the crown and forehead regions; thus when transplanted, these hair follicles will maintain their original characteristics.

For many years, single-strip excision—the process of cutting a strip of skin out of the donor area and harvesting the individual follicular units—has been the most common follicular unit graft technique; however, it poses a number of limitations. The procedure is fairly invasive, requiring the physician to be proficient in hemostasis, surgical techniques, and wound management. This strip-harvesting approach usually is associated with 2 to 3 days of mild to moderate pain, 5 to 7 days of soreness, and usually 1 to 3 months of numbness and tightness in the donor site. Additionally, the resulting linear scar may cause difficulty in repeated follicle harvests, and patients must maintain a longer hairstyle if they do not want the scar to be visible (Figure 1).

In the last 2 decades, the field of cosmetic surgery has shifted toward minimally invasive techniques that provide

From the University of Colorado School of Medicine, Aurora, and Hair Sciences Center of Colorado, Greenwood Village.

Dr. Harris is a consultant and principle investigator for Restoration Robotics, Inc.

Correspondence: James Harris, MD, 5445 DTC Pkwy, Ste 1015, Greenwood Village, CO 80111 (jaharris@hsccolorado.com).

Figure 1. Clinical photograph demonstrating a visible linear scar in a patient with short hair.

the benefits of reduced pain, discomfort, and postoperative recovery periods; this same trend is now evident in hair restoration surgery. Technologic advances have led to a technique called follicular unit extraction (FUE), which allows single follicular units to be extracted with small dermal punches to avoid the need for sutures, staples, or linear incisions in the donor area. Follicular unit extraction initially was performed using sharp dermal punches and manual rotation, but a commercially available powered system called Neograft (Neograft Solutions, Inc) was developed as well as several other powered rotary systems. Anecdotally, sharp punch FUE techniques produced excessive rates of follicle transections in the hands of inexperienced physicians. To address this shortcoming, the SAFE (surgically advanced follicular extraction) System℠, a technique and instrumentation that allows more successful FUE graft harvest by using blunt rather than sharp dissection instrumentation, was developed.[3] In a survey of 149 physicians, the FUE technique constituted 22% of all hair restoration surgeries.[1]

Follicular unit extraction seems to be the natural next step in hair restoration techniques, but so far its adoption has been slow, primarily because of the special training and commitment to practice that are required for proficiency. Unfortunately, most physicians are hesitant to invest the time; therefore, few surgeons offer the procedure. Not only is the analysis of the angle, direction, and type of hair follicle a complex process that requires judgment from years of experience, but the process itself is tedious and can take a long time to complete until the surgeon has had substantial practice.

The ARTAS System (Restoration Robotics, Inc) was pioneered after years of development that included a team of hair restoration physicians, robotic engineers, and clinical experts. It is a computer-assisted, image-guided system that enables consistent and reproducible results while resolving the challenges inherent to the FUE technique. It received 510(k) clearance from the US Food and Drug Administration in 2011 for harvesting hair follicles from the scalp in men diagnosed with androgenetic alopecia with black or brown straight hair. The ARTAS System uses 2 sets of cameras to enable assessment of every follicular unit in its field of vision and uses sophisticated software algorithms to choose and dissect the individual follicular units safely and efficiently under the guidance of the physician. The ARTAS System uses a small sharp inner needle to score the skin followed by the insertion of a blunt outer dissection punch, similar to the SAFE System, to harvest individual follicular units while maintaining low follicle transection rates.

CASE REPORTS

Patient 1

A 45-year-old man with diabetes mellitus presented with a history of hair loss beginning in his mid 30s. He previously had not taken medication for hair loss but intended to start after surgery. The patient had a maternal and paternal family history of hair loss. On examination the patient demonstrated a Norwood class 4a hair loss pattern (Figure 2). The patient elected to undergo a hair restoration procedure utilizing FUE and the ARTAS System.

On the day of surgery, the donor area was prepared by cutting the patient's hair to a length of 1 mm, and lidocaine 1% with 1:200,000 epinephrine solution was used to perform a ring block in the occipital donor area. A skin tension device with fiducial markings—printed symbols that provide a frame of reference for the imaging system—was placed in the donor target area (Figure 3). The device stabilized the skin to allow for more precise entry of the dissection needles into the skin and also placed the fiducial markings in position to be recognized by the system. Commands were entered into

Figure 2. A 45-year-old patient with Norwood class 4a hair loss before treatment.

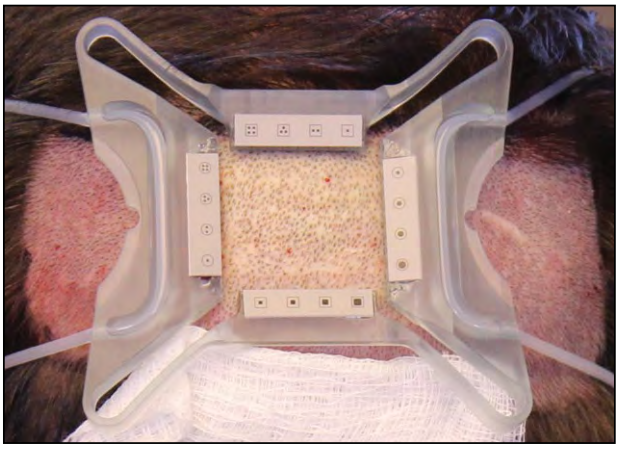

Figure 3. Skin tension device with fiducial markings—black and white square and circular figures—in place at the donor site.

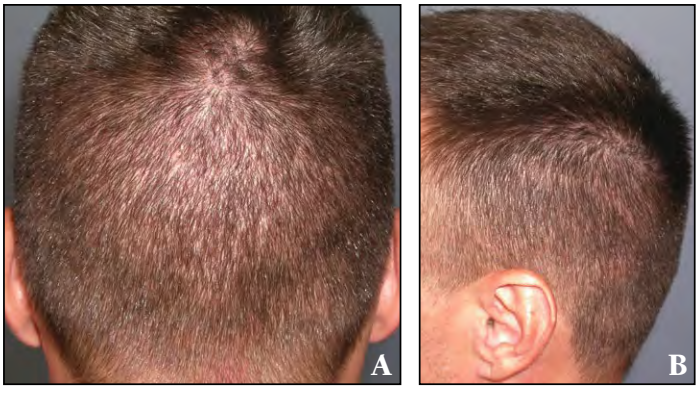

Figure 4. The donor area 10 days after follicular unit extraction showing minimal scabbing and some growth of the remaining donor hair in the occipital (A) and parietal areas (B).

the system to analyze the position of the follicular units, compute the follicular unit density, and assess the angles and directions of the hairs within the follicular units. Algorithms to guide the system for extraction patterns and densities were used to identify appropriate target units. Under physician control and direction, the targeted units were dissected at rates of 750 to 1000 grafts per hour. Minor adjustments to dissection depths and angle limits were made during treatment at the physician's discretion. Any targeted follicular unit easily could be skipped by an operator override.

The ARTAS System harvested individual follicular units in a random pattern according to the parameters specified by the physician; some of these parameters can be adjusted by the physician as required, such as the depths of the sharp needle and blunt punch, the spacing between each harvest site, and the approach angle of the dissecting needles. In this particular patient, 20% of the available follicular units in the targeted donor area were harvested. The grafts were removed from the skin and implanted using jeweler's forceps into parallel recipient sites created with 0.8- and 1-mm chisel blades.

The patient received 894 follicular unit grafts in the frontal area. The surgical time required to harvest the follicles was 1.5 hours, resulting in an effective harvest rate of 596 follicular units per hour. Within 2 days of the surgery, the patient did not experience any pain or discomfort and was able to resume all normal activities 3 days after surgery. Within 10 days, scabbing in the donor site was minimal, and the patient's hair had grown to sufficient length so that there was minimal visible evidence that he had undergone hair restoration surgery (Figure 4). Nine months following treatment he presented with notable hair growth in the frontal area, and the restoration treatment resulted in a Norwood class 3 hair loss pattern (Figure 5).

Patient 2

A 40-year-old man presented with a history of hair loss beginning in his mid 20s. The patient reported a maternal family history of hair loss and no prior use of medication for hair loss. On examination the patient demonstrated a Norwood class 4 hair loss pattern (Figure 6A). Prior to his consultation, the patient heard about the advantages of FUE and was interested in surgical hair restoration via image-guided FUE and the ARTAS System.

The patient underwent 2 surgeries using the ARTAS System. The first was in January 2010, during which 755 follicular unit grafts were harvested and transplanted in the frontal area of the scalp, and the second surgery was performed in July 2010, during which 898 follicular unit grafts were transplanted to advance the frontal hairline. The combined time for harvesting 1653 total follicular units was 3 hours, resulting in an effective harvest rate of 551 follicular units per hour.

Within 2 days of each surgery the participant experienced no pain or discomfort. One year following treatment, the patient presented with a Norwood class 3 hair loss pattern, which was the treatment goal (Figure 6B).

COMMENT

These patients represent the most common candidates for hair restoration surgery; however, these cases are unique because of the method used for harvesting the follicular units. Follicular unit extraction has piqued the interest of both patients and physicians for many years because of its potential to provide a less invasive means of harvesting hair follicles, which allows for a quicker recovery time and no linear scarring. This technique also has been considered to be so complex and tedious that

Figure 5. The top of the scalp after hair restoration surgery with notable hair growth in the frontal area.

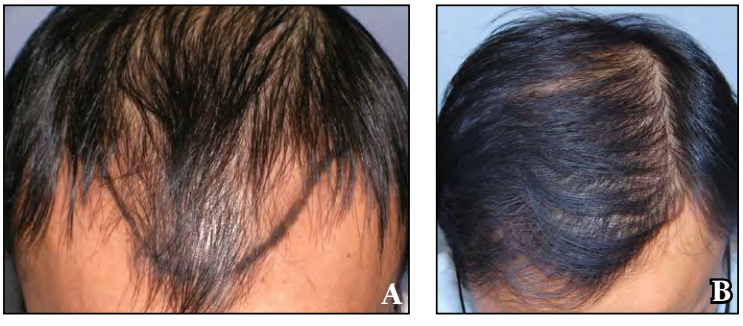

Figure 6. A 40-year-old patient before (A) and 1 year after hair restoration via follicular unit extraction (1653 total follicular units) using the ARTAS System (Restoration Robotics, Inc)(B).

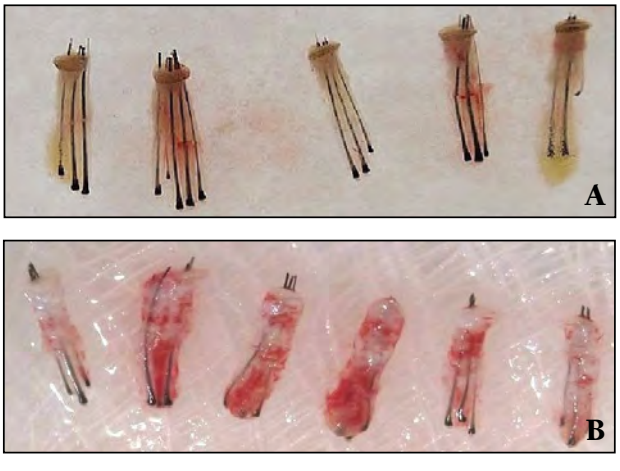

Figure 7. Standard follicular unit grafts demonstrating a noticeable lack of fatty tissue around the follicles (A) compared to ARTAS System (Restoration Robotics, Inc) follicular unit grafts, which have substantially more fat around the follicles (B).

FUE has never been popular among physicians. If patient 1 had underwent manual FUE by a surgeon who was new to the FUE technique, he likely would have spent 6 hours in surgery instead of 3 hours, and the quantity of transected follicular units would have been much higher. The ARTAS System offers a substantial reduction in surgical time, often by a factor of 2 to 3 times, and produces higher-quality grafts regardless of the surgeon's experience level.

One of the challenges that is associated with manual FUE is that that the physician must look at a specific area of the scalp, analyze the direction in which follicles are pointed, make a judgment regarding the angle at which the follicles emerge from the surface, and then decide how far apart the extraction sites should be. The physician also must manually center the dissecting punch over the emerging hair and determine both the correct amount of pressure to apply and ideal depth at which to insert the dissecting tool. Instead of relying on human judgment and estimation, the process is accomplished more precisely by the vision and follicular unit assessment algorithms of the ARTAS System. Physician fatigue, which can result in lapses of judgment and lead to an increase in follicle transection rates, is not really an issue when using this system. Even the most experienced surgeon can benefit from the precision of this technology.

In addition to physician fatigue, another criticism of manual or powered FUE is that the follicular units often are stripped of fatty tissue (Figure 7A), which is associated with poorer transplant survival rates. The inherent qualities of the blunt dissection system produce grafts that have more fat around the follicles, thus improving the likelihood of graft survival (Figure 7B).

CONCLUSION

A solution to the complex and tedious nature of manual FUE procedures, the ARTAS System is an assistive device that will allow more physicians and patients to take advantage of the benefits of minimally invasive cosmetic procedures. The technology also requires fewer staff and physician hours yet still commands a premium price. Patients will benefit from quicker healing times, excellent results, and wider availability of the procedure. The ARTAS System has the potential to create a monumental change in hair restoration procedures.

REFERENCES

1. International Society of Hair Restoration Surgery. *2011 Practice Census Results.* Geneva, IL: International Society of Hair Restoration Surgery; 2011. http://www.ishrs.org/PDF/FinalPracticeCensusReport7_11_11.pdf. Accessed May 11, 2012.
2. Orentreich N. Autografts in alopecias and other selected dermatological conditions. *Ann N Y Acad Sci.* 1959;83:463-479.
3. Harris JA. New methodology and instrumentation for follicular unit extraction: lower follicle transection rates and expanded patient candidacy. *Dermatol Surg.* 2006;32:56-62.